



The role of orthodontics in forensic science

Raid Razak Ali AL-Kafaji, Thajer Kassim Ali

Dentistry Collage, Karbala University, Iraq

Abstract

Forensic dentistry is one of the new sciences and concepts that have emerged in most countries of the world. It is used in the scouting side of the forensic evidence to find out many facts related to personalities whose identity is to be revealed, or to know the crime if it occurs. It was adopted as a step that encouraged students to study the facts related to it in terms of linking forensic medicine to the branch of orthodontics, which is one of the branches of dentistry. While there are various fields in dentistry related to this new branch, orthodontics also has an important role in forensic science. In this article, some of the concepts that researchers have been involved in according to a set of modern scientific studies, which can be used to develop experiences and benefit from successful experiences and apply them, and the relationship of orthodontics in forensic medicine and the bite mark was discussed.

Keywords: orthodontics, forensic science, bite mark

Introduction

Orthodontics is one of the specialties that are important in dentistry, as it is concerned with the alignment and consistency of the teeth and jaws to give a beautiful smile and oral health. Mostly, the dentist recommends paying attention to orthodontics in order to improve the patient's condition to be in a suitable physical appearance (oro-facial). This specialty has been developed through orthodontic treatment, and the correction of problems associated with it in certain cases such as crooked or crowded teeth, excessive bites, incorrect position of the jaw, in addition to disorders of the jaw joints. And since orthodontics is concerned with the study of the teeth, the face and jaws, and the mold of the teeth of individuals, then there is a so-called legal approximation of the face, which is expressed by (FFA). What is similar to the real face of the deceased, and this is what is used for the purposes of forensic medicine and archaeological discoveries (1). Forensic dentistry is of great importance compared to other sciences, and it is one of the dental professions that is associated with the legal profession. Stored dental materials, which cannot rot, can be used in lawsuits by dentists, especially in procedures for identifying skeletal bodies only after they have undergone rotting (2, 3). Forensic dentistry is the application of the dental field to the civil and criminal laws that are enforced by the police agencies of the criminal justice system. Forensic dentists provide assistance to investigative agencies that ask them to play their role in identifying the remains of the body of any unidentified and unknown person, thus determining the identity of the owner of the fragmented body. It is obvious that forensic dentists are required to play their role in determining some information about the body, such as age, race, occupation, and other information related to age and its treatment, and through all of what has been mentioned, the economic and social status of the unidentified person is known. There is great importance in the characteristics of the teeth towards criminal cases, it helps to clarify many things from the legal point of view, and in order to get to know these important advantages we must understand the anatomical parts and the details of the texture of the tooth and its importance in this field. From an anatomical point of view, the teeth consist of three main parts, and these parts are: the enamel layer, the dentin layer, and the pulp of the tooth. Each of these layers has a set of unique features that distinguish it from others. The enamel layer is the outer layer of the tooth, which is externally visible inside the oral cavity. It is the most solid substance in the human body in general, and this hardness makes the enamel layer Dead, renewable in case it is damaged, and it consists of organic crystals. As for the layer of ivory, it is a living substance that renews and grows because it is made of organic crystals as well. It must be noted that the percentage of organic matter in it is large in a way that allows the presence of living cells that work to deposit ivory on a continuous basis. As for the last layer, it represents the pulp of the tooth, in which the veins, arteries and nerves are collected, and it is what nourishes the dentin layer. Teeth are formed in newborns after the third month of life, and continue until the age of twenty-three. These stages are known as the time period for each stage of tooth growth. Among the most important features of the teeth is their presence inside the oral cavity, which constitutes a protective factor that protects them from external factors such as fires, for example, and other accidents that lead to damage to the entire external tissue of the body, or change the outward characteristics of the person for certain reasons. The teeth are mostly unaffected, and they maintain their strength and their outward, physiological, and anatomical characteristics. These characteristics are what made the teeth of great importance in judicial evidence. It is easily possible to assess a specific forensic case of an individual whose remains were

cremated using some information obtained from radiographs that reveal details inside the mouth during orthodontic treatment (4). The information that the dentist gives him about revealing the identity of the unknown individual is considered the report adopted by the specialized agencies in the field of forensic evidence to arrive at a set of facts that can be used in the final result of detecting the crime.

What is required of the forensic dentist to do

1. Identify the cases resulting from accidents and disasters through the dental records of unknown persons whose mutilated bodies that have been preserved are to be identified in order to reach integrated or semi-integrated results that may eventually lead to knowledge As much evidence as possible to identify the unknown individual. Teeth were chosen as a means of forensic evidence because of their great resistance to natural factors such as fires, explosions, and others. The forensic dentist will draw up a list documenting complete information about the person's teeth, the type of fillings, and how the restorations used to be compared with records containing previous dental information, even if the number of teeth remaining in the unknown body is few, through which we may be able to confirm the identification of the person's age. Oral health, and other habits and their impact on the mouth, such as smoking. And in some cases, through only one tooth, a person is identified. And in cases of complete tooth loss, we can benefit from any remaining dental landmark by means of oral radiography.
2. Knowing and determining the true identity of the offender by studying the dental criminal effects. 3. Through forensic dentistry, sex can be determined.
3. Ages can be known and estimated by checking the development of tooth eruption, and comparing eruption tables. The estimate is usually correct or with a possible error rate estimated at approximately 10%, and the extent of the gradual growth of dental roots is used in determining or estimating ages.
4. Detecting traces of crime in cases where biting occurs, and it is considered evidence of great importance, and there is a fixed rule that says that bruises are types, each type has a semi-circular shape with a diameter determined from 4-5 cm, which in turn represents a trace of a bite, They vary according to their severity, some of which make the area bleed, some of which cause a bruise or wound, and some of them cause a complete cut of tissue.
5. It helps in examining the traces of the crime by means of the details of the print or template.
6. The possibility of reshaping the anatomical features of the faces, and this method is used in the case of insufficient dental evidence when comparing it with previous dental records. It also gives us information about the age of the unidentified individual, as well as the gender, in addition to the social status, so the appearance of the skull is determined, thus has determine race.
7. Benefiting from forensic dentistry in cases of malpractice, such as negligence or fraud.
8. Estimating the duration of wound healing in oral and maxillary lesions, and knowing the estimated percentage of damage in those injuries.
9. Take advantage of it in estimating the type of permanent impairments that the mouth is exposed to.
10. Estimating the costs required in dental treatment in case of injuries, and the total value of compensation for missing teeth, and knowing how many times it must be changed during the years of life to remain in good condition.
11. Determination of blood properties by examining the dental pulp.
12. It is used to identify some genetic features of the teeth using certain techniques. 18. It is useful in cases of determining parentage and establishing paternity.
13. It serves to know a number of habits associated with the mouth, such as smoking.
14. Through it, the profession of the individual is determined in certain cases based on some dental signs, such as the presence of traces of sewing pins.
15. It is useful in discovering some cases that occur, such as poisoning associated with oral manifestations, such as poisoning caused by lead.

Bite-Marks

Bite-marks defined as a marks made by the teeth either alone, or combined with other parts of mouth (5). In forensic orthodontics, the parts that deals with an identification of bite-marks have a high importance in terms of evidentiary value. In several countries of the word, there are many number of population asking orthodontics' treatment, such as western population. the discrepancies that related with the forensic odontology by accuracies, reliability, and investigatory science, so bite-marks are produced essentially through many aspects (6, 7):

- As a result of physical and sexual assaults by a particular person with a girl or a child, or attempted rape, and interpersonal quarrels.
- As a result of self-defense against aggression caused by physical harm, such as biting the tongue during epileptic fits or falling from a high place (7).
- Marks resulting from dental pressure between the inner and front edge of the teeth.
- The presence of scratches and wounds, which is evidence of a contradiction in the regularity of the teeth, as in fractures or restorations of the teeth.
- The marks and bites are classified into categories A, B, and C (8).
- There is a well-defined mark resulting from a normal or sexual bite, it is born slowly.
- Aggressive cues are formed quickly and forcefully, they leave traces on the tissues.

- Most of the aggressive cues may affect tissues, as happens on the ears, nose and other organs. Therefore, the guidelines of the American Board of Forensic Dentistry (A.B.F.O) (9), show that there are different classifications of bite marks according to the characteristics and boundaries of the jaws, as well as the shape and size of the braces, and whether there are missing teeth, or the spacing between the teeth if any. , Noting the presence of extra teeth or not, the noticeable rotation of the teeth that may show some anatomical parts coming out, and the presence of special qualities in the teeth such as fractures and so on.

Forensic dentistry and bite-marks

Forensic bite-mark evidence has been used to identify criminals in many cases. It has become clear how we can know the offender from the bite marks that are found on the victim's body, or on the food left by the criminal at the crime scene, by comparing between the cues trace and the dental impression taken from the suspected person (10). There are a number of factors that may affect the accuracy of knowing and determining the impact of the bite, the most important of these factors are:

1. Changes that may occur in the living body over time.
2. Possible effects that may arise from the place where the bite mark was found.
3. Damage is generated in the soft tissues of the body.
4. The similarity in the teeth of a large number of individuals.

In addition, there are other factors that also affect the discovery of criminal cases through forensic dentistry sciences, and they include (11, 12, 13):

1. Inaccurate imaging of the case to be detected.
2. Failed dental bite-marks in many cases for any reasons.
3. Errors that occur in the rest of the dental measurements and their useless results.

Examples of orthodontic forensic dentistry

The first case represents a fire accident that happened to the body of a person who was completely inspected and was only identified by specialized experts from orthodontic forensic dentistry, as shown in figure no. 1:



Fig 1: Shows the skull of a completely burnt person and was identified by orthodontic forensic dentistry.

There are examples in which the detection of crime is clarified by matching the orthodontic edition, so that the most important specifications of the criminal are known through the data obtained by the criminal dentist when verifying the merits of the crime, as shown in figure no. 2

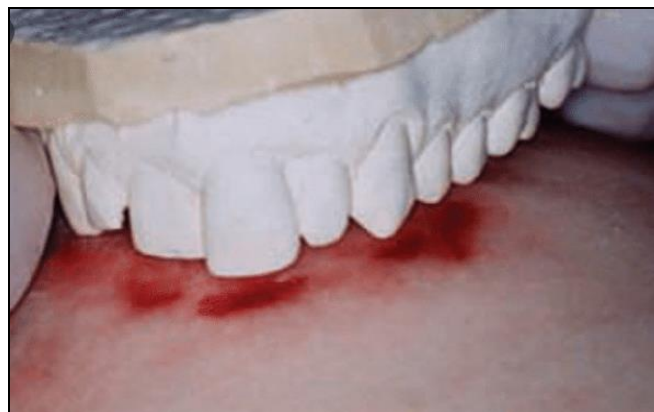

Fig 2: It shows the conformity of the dentures of the suspect to the location of the bite in the victim's body.

When investigating a specific criminal case through orthodontic forensic dentistry, all information obtained by the competent team assigned to this special task must be preserved, stored and documented, and all the steps that have been taken, being the basic and important means, must be photographed. Which led us to know all the required facts and results and thus lead to the knowledge of the perpetrator or the victim. Figure no. 3 shows us a group of dental impressions that are used in orthodontic dentistry, which may be left and neglected in the absence of criminal investigations about a specific accident, while they are considered very important when they are collected, preserved and documented, so they are the strong evidence to know the facts that It was hidden from the relevant authorities.

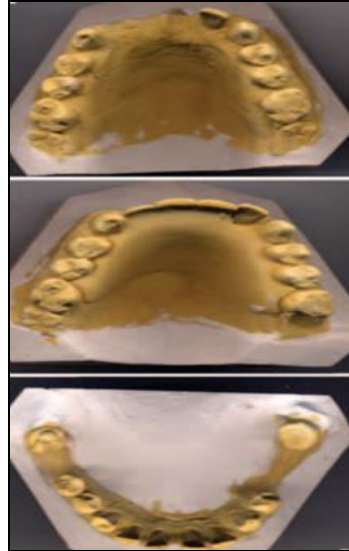


Fig 3: to show some cases of normal orthodontics dentistry.

Tooth is a source of DNA

It is possible to obtain a sample of the DNA of an unknown person by analyzing a number of biological materials in the body, such as human blood, various tissues in the body, semen, hair roots and nails, teeth and bones of various kinds, and saliva that is secreted in the oral cavity, as shown in figure no.4. There are also different sources in the mouth, through which DNA can be obtained to benefit from it in criminal cases as shown in figure no.5.

For a forensic dentist to obtain a person's DNA through a dental sample, it is considered one of the best and most powerful main sources of it, because it has the ability to withstand and persist in the face of changes, as the teeth are much better than the bones of the skeleton. We can obtain of DNA from tooth of victims and then compared with the main samples that obtained from any person, to know finally many information of the family members (14, 15, 16). But with all of the above, we must know that DNA analysis is very expensive and that it is difficult or impossible to completely differentiate between identical twins (17).

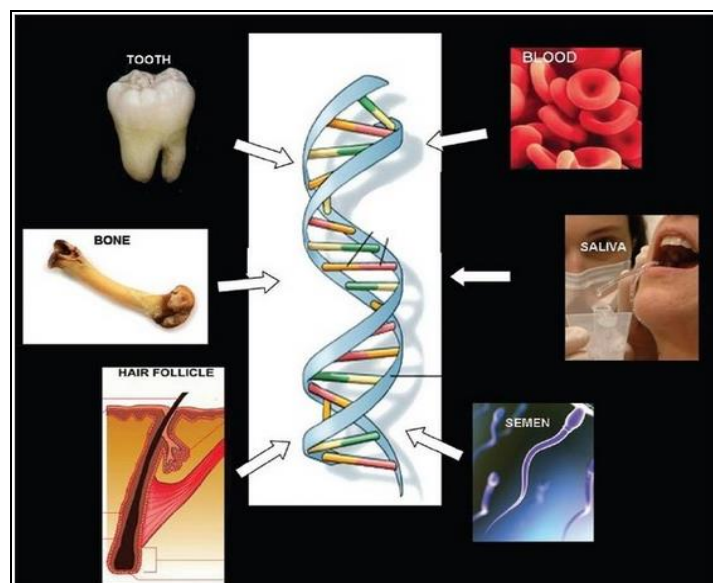


Fig 4: DNA Sources of forensic analysis.

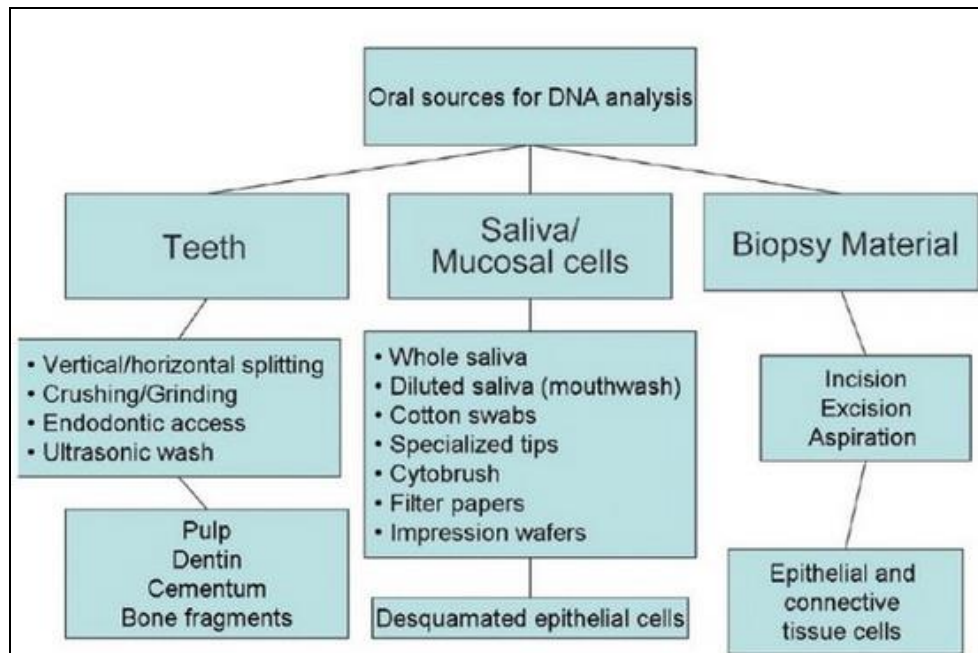


Fig 5: to show methods of Specimens collection from different oral sources.

References

1. Taylor KT (2000) Forensic art and illustration, 1st edn. CRC Press, United States.
2. Department of health (2009) Records management (Part 2), NHS Code of Practice.
3. Silva RF, Cruz BVM, Daruge Júnior E, Daruge E, Francesquini JL. The Importance of dental documentation in human identification. *Acta Odontol Venez*,2005;43:67-74.
4. Silva RF, Chaves P, Paranhos LR, Lenza MA, Daruge Júnior E. Use of orthodontic records in human identification. *Dental Press J Orthod*,2011;16:52-57.
5. MacDonald DG. Bite marks, recognition and interpretation. *J ForenSci*,1979;14:229.
6. Clark DH. Bite marks in tissue and in inanimate objects: analysis and comparison. In: *Practical Forensic Odontology* (3rd Edtn). Wright, UK, 1980.
7. Onmura T. Examination of bite wounds in reference to a rape and murder case of a young girl. *ActaCrim Med Deg Jap*,1968;34:51.
8. Gustafson G. *Forensic odontology*. Staples Press, London, UK, 1966.
9. <http://www.abfo.org/resources/id-bitemark-guidelines>.
10. Verma K, Joshi B, Joshi CH, Rejeet Paul MP. Bite Marks as Physical Evidence from the Crime Scene-An Overview,2013;2:605.
11. Kouble RF, Craig GT. "A comparison between direct and indirect methods available for human bite mark analysis" *Journal of Forensic Science*, 2004.
12. Al-Talabani N, Al-Moussawy, ND, Baker FA, Mohammed HA. Digital analysis of experimental human bitemarks: application of two new methods" *Journal of forensic sciences*,2006;51(6):1372-5.
13. Martin-de las Heras S, Valenzuela A, Valverde AJ, Torres JC, Luna-del-Castillo JD. "Effectiveness of comparison overlays generated with DentalPrint software in bite mark analysis" *Journal of forensic sciences*,2007;52(1):151-6.
14. Rajshekar M, Tennant M. The Role of the forensic odontologist in disaster victim identification: A brief review. *Malays J Forensic Sci*,2014;5:78-85.
15. Kolude B, Adeyemi BF, Taiwo JO, Sigbeku OF, Eze UO. The role of forensic dentist following mass disaster. *Ann Ib Postgrad Med*,2010;8:111-7.
16. Manjunath BC, Chandrashekar BR, Mahesh M, Vatchala Rani RM. DNA profiling and forensic dentistry – A review of the recent concepts and trends. *J Forensic Leg Med*,2011;18:191-7.
17. Metcalf RD, Klim-Lemann J. Overview of forensic odontology. *J Calif Dent Assoc*,2015;43:295-301.