



Thermal management in third molar extraction: Impact of irrigant temperature on postoperative outcomes

Dr. Bhagvandas Rai*, Dr. A B Rai, Dr. Vasu Bhut, Dr. Himanshu Gupta, Dr. Rashi Panjwani, Dr. Rajvirsinh Parmar

Department of Oral and Maxillofacial Surgery University, Paher University, Rajasthan, India

Corresponding Author: Dr. Bhagvandas Rai

Abstract

The surgical extraction of impacted mandibular third molars is among the most frequently performed outpatient oral surgical procedures. In this study, 40 patients requiring removal of impacted lower wisdom teeth were treated under local anesthesia. Normal saline was used as the irrigating solution in two temperature variations: refrigerated at 8°C and at room temperature. All patients underwent standardized surgical protocols and postoperative medication regimens. Postoperative outcomes, including pain, swelling, infection, and wound healing, were evaluated and compared on the 1st, 3rd, and 7th postoperative days. Findings revealed that the use of cold saline irrigation significantly reduced postoperative complications and promoted faster healing following third molar surgery. Further large-scale studies with greater sample sizes are suggested to validate the effectiveness of cold saline as an irrigating solution in impacted third molar surgeries.

Keywords: The surgical extraction of impacted mandibular third molars are among the most frequently performed outpatient oral surgical procedures

Introduction

Third molars, commonly known as wisdom teeth, are the most frequently impacted teeth in the human dentition. This is largely due to their posterior anatomical positioning and a combination of evolutionary and developmental factors—both phylogenetic and ontogenetic. The mandibular third molars typically begin developing in the ramus of the mandible around the age of seven. They are the last teeth to erupt into the oral cavity, although the timing of eruption can vary based on genetic and racial factors.

The surgical extraction of impacted mandibular third molars is one of the most commonly performed minor procedures in oral and maxillofacial surgery. While many impacted third molars remain asymptomatic and may never require intervention, others can lead to pain, infection, dental crowding, or the development of pathological lesions. When removal is indicated, the complexity of the procedure can vary significantly. Some extractions are straightforward and can be managed using elevators and forceps alone. However, more often, surgical removal is necessary. This involves raising a mucoperiosteal flap and removing surrounding alveolar bone to allow adequate access to the impacted tooth. Surgical approaches help improve access, reduce intraoperative risks, and support better postoperative outcomes.

Despite its routine nature, third molar surgery is not without potential complications. These may be iatrogenic, such as injury to the inferior alveolar or lingual nerves, adjacent tooth damage, or jaw fractures. More commonly, inflammatory complications arise, including pain, swelling, hematoma, trismus (restricted mouth opening), infection, delayed healing, and dry socket (alveolar osteitis). Such complications can significantly impair a patient's quality of life, hindering normal oral functions like chewing, speaking, and maintaining hygiene during the recovery period.

Nevertheless, the extraction of third molars offers multiple health benefits. It helps prevent dental caries and periodontal disease in hard-to-clean posterior areas. Furthermore, removal may assist in orthodontic and orthognathic treatment plans and reduce the risk of more serious conditions such as dentigerous cysts and root resorption of second molars. With appropriate management, third molar surgery contributes to long-term oral health.

Among postoperative complications, alveolar osteitis, or dry socket, is one of the most painful and common. It typically occurs within three to five days after surgery and presents as severe, radiating pain due to the dislodgement or premature loss of the blood clot that normally protects the bone within the extraction socket. Contributing factors include smoking, poor oral hygiene, and notably, thermal trauma from excessive drilling without proper cooling, which may delay healing.

Thermal management is therefore a critical aspect of third molar surgery. High-speed rotary burs used to section bone or teeth can generate significant heat—temperatures as high as 47°C in under a minute. Prolonged exposure beyond this threshold can result in heat-induced bone necrosis, negatively impacting healing and increasing the likelihood of complications. To counteract this, continuous irrigation with cooling solutions during drilling is essential. It reduces heat buildup and improves visibility during surgery by flushing debris from the surgical field.

Various irrigation fluids have been utilized, including normal saline, Ringer's lactate, povidone-iodine, and distilled water. The ideal irrigant should be isotonic, antiseptic, non-toxic, non-irritating, readily available, and cost-effective. Normal saline is widely used for this purpose as it meets most of these criteria. Although it lacks direct healing properties, it effectively cools the surgical site, clears debris, and maintains tissue cleanliness. In contrast, chlorhexidine offers strong antimicrobial effects and long-

lasting activity but is less commonly used for intraoperative irrigation. Distilled water, though pure, is hypotonic and may cause tissue damage due to cell lysis.

Recently, the use of cooled normal saline, maintained at approximately 4°C, has gained interest. It offers enhanced thermal protection, stimulates bone healing by promoting osteoblast activity, and may reduce postoperative pain and swelling. These advantages have led to its increasing adoption in oral surgical practice.

Based on these insights, a prospective analytical case series study was conducted at the Oral and Maxillofacial Surgery Department, Pacific Dental College and Hospital, Udaipur. The study aimed to compare the effects of cold saline versus room-temperature saline as irrigants during third molar extractions, evaluating outcomes such as postoperative pain, swelling, healing, and overall patient recovery.

Materials and Methods

The present study is a prospective study. The proposed study was approved by the Institutional scientific and Ethical Review Board and prior approval was procured before commencement of the study (IEC approval) and written consent was obtained. This study entailed the use of cold saline (4°Celsius) for one group and normal saline (room temperature) for the other group of patients for the removal of impacted mandibular third molars. Normal Saline is the most commonly used irrigating solution. A surgical straight hand piece connected to a micromotor would be utilized for bone cutting with the aid of external saline irrigation. Rotary speed will range from 25,000 to 35,000 revolution per minute. A tungsten carbide round bur (no.8) and straight fissure bur (no.702) was used for bone cutting.

The present study was conducted on 20 patients with the informed consent in the Department of Oral and Maxillofacial Surgery, Pacific Dental College and Hospital, Debari Udaipur, Rajasthan India.

The patients in this study were divided into two groups.

Group I: 10 Individuals with impacted mandibular third molar teeth for study group, where cold saline (4° celsius) was used.

Group II: 10 Individuals with impacted mandibular third molar teeth for control group, where normal saline (room temperature) was used.

Patients falling under the age group of 18 to 55 years with impacted Mandibular third molar with similar difficulty index as given by Pederson with the absence of acute Inflammatory symptoms, who are non-smokers and patient with healthy dental status, patient ready to sign the informed consent, patient that were ready to come for follow up visits as and when required were included in the study.

Medically compromised patients with systemic diseases such as diabetes, cancer or renal failure, impacted molars with pathology and periapical infection, alcohol and tobacco abusers, pregnant females and lactating females, restricted Mouth Opening (below 30 mm), not willing to participation

in study and follow up were excluded from the study. 20 patients having impacted mandibular 3rd molar, requiring removal of impacted teeth with similar difficulty index, depth and relationship with ramus were taken up for the surgery, in which selection of patients were done randomly.

After recording the case history, intra oral periapical radiograph or orthopantomograph was taken and informed consent was obtained. 2% lignocaine hydrochloride with adrenaline in 1:80,000 dilution was used for Inferior Alveolar, Lingual and Long Buccal nerve blocks; after the patient was prepared under standard aseptic conditions.

Ward's incision was placed using no.15 Bard-Parker blade and a full thickness mucoperiosteal flap was reflected using Howarth's periosteal elevator.

In Group I i.e., the study group, the impacted teeth were surgically extracted using rotary burs. Precise bone cutting was done using SS White round (no 8) carbide bur and straight fissure (702) carbide bur of 1.5mm diameter and 7mm head length with a straight hand piece at 22,000 rpm with the irrigating solution as Cold Normal saline at the temperature of 4° celsius and the tooth was removed. The wound socket was debrided and irrigated using a combination of povidone-iodine and normal saline. Wound closure was done using non-resorbable 3.0 black braided silk sutures. Postoperatively, patients were prescribed Amoxicillin (500 mg) + clavulanic acid (125 mg) (BD); and Tablet. Aceclofenac (100Mg) + Serratiopeptidase (15Mg) + Paracetamol (325 Mg) (BD); Tablet Ketorolac Tromethamine (SOS) daily for five days.

While in Group II, The Control group, the impacted teeth were surgically extracted using rotary burs. Precise bone cutting was done using SS White round (no 8) carbide bur and straight fissure (702) carbide bur of 1.5mm diameter and 7mm head length with a straight hand piece at 22,000 rpm with the irrigating solution as Normal saline and the tooth was removed. The wound socket was debrided and irrigated using a combination of povidone-iodine and normal saline. Wound closure was done using non-resorbable 3.0 black braided silk sutures. Postoperatively, patients were prescribed Amoxicillin (500 mg) + clavulanic acid (125 mg) (BD); and Tablet. Aceclofenac (100Mg) + Serratiopeptidase (15Mg) + Paracetamol (325 Mg) (BD); Tablet Ketorolac Tromethamine (SOS) daily for five days.

Pre-operative Parameters Recorded

Pre-operative assessments such as facial measurements, inter-incisal mouth opening will be recorded as a baseline measurement and for post-surgical comparison on postoperative days 3rd and 7th day.

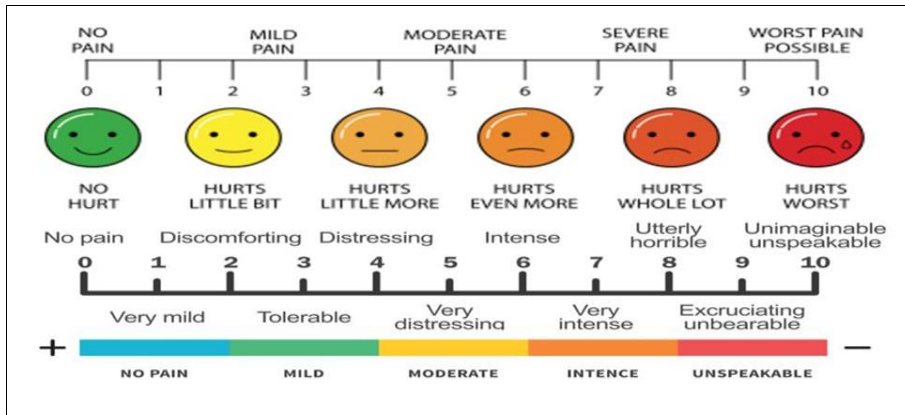
Post Operative Parameters Recorded

Post-operative pain was evaluated based on the 10cm Visual Analogue Scale (VAS) on the 3rd and 7th post operative days;

0-absence of pain,

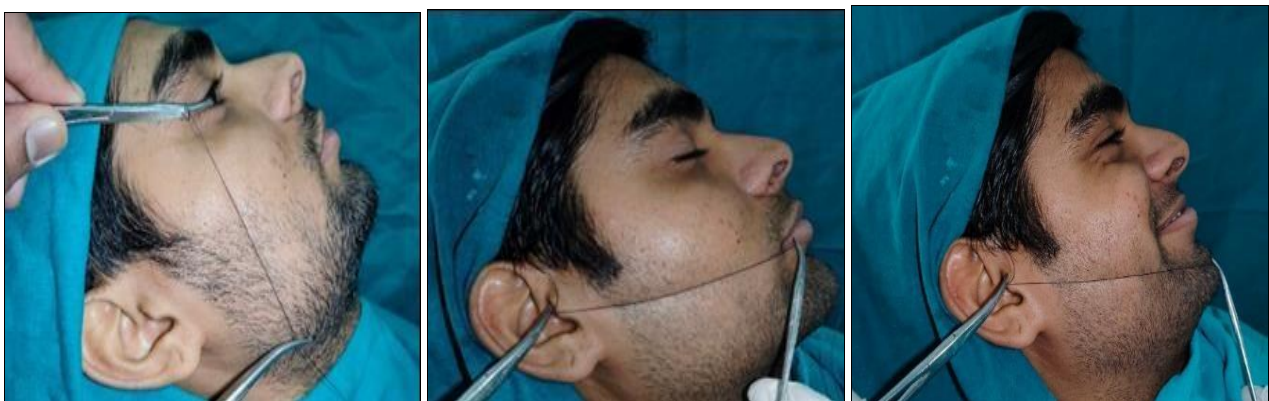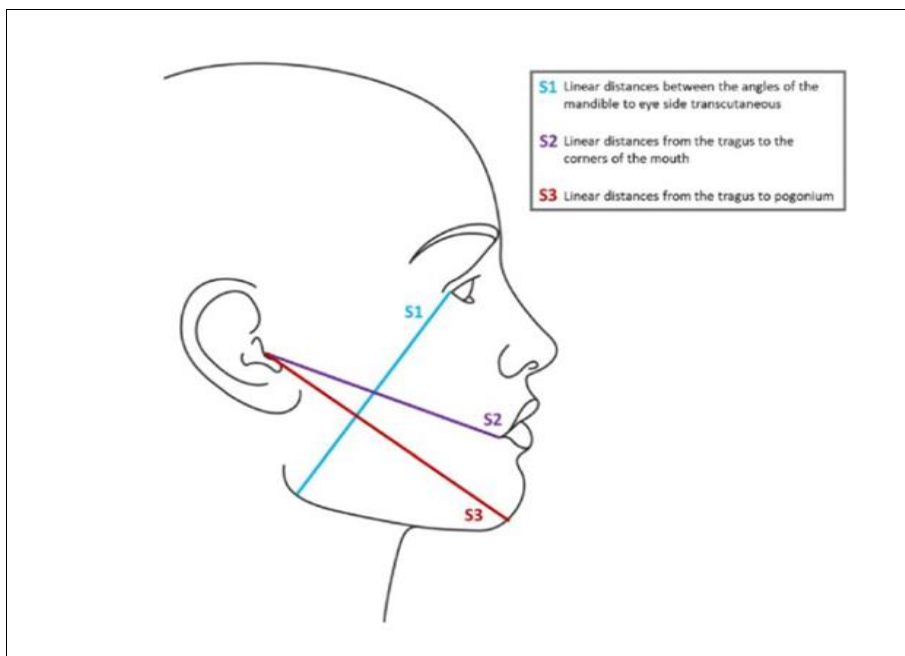
10-most severe pain.

Post-operative Pain was recorded using Visual Analogue scale.

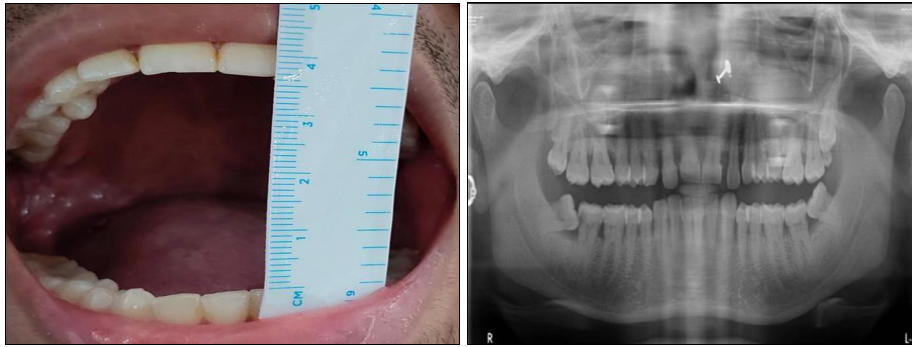

Facial measurements will be recorded By using GABKA AND MATSUMARA SCALE with measuring tape by taking the mean of the distance from the lateral corner of the eye (A) to angle of the mandible (B) (AB=S1), Tragus (C) to the corner of the mouth (D) (CD=S2) and Tragus (C) to soft tissue pogonion (E) (CE=S3) of facial swelling. This measurement was done prior to surgery along the natural

convexity of the patients face as a reference measurement and was also recorded on 3rd and 7th postoperative days. Trismus was evaluated based on the distance (in milimeters) between the incisal edge of the upper and the lower central incisors at maximum mouth opening on 3rd and 7th post operative days.

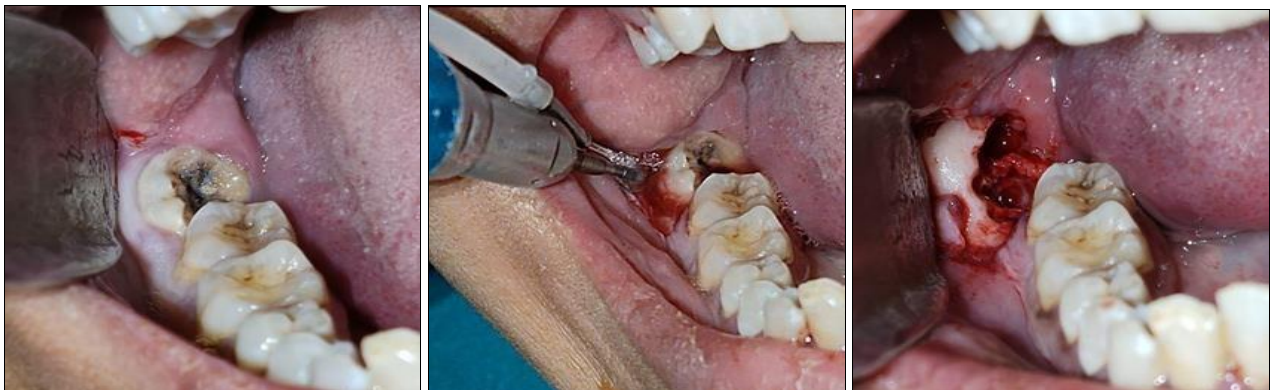

Facial Measurements



Mouth Opening

Radiograph



Intra Operative Procedure

Result

Demographic details

The study comprised of 20 patients requiring removal of lower 3rd molar (11 males and 9 female) in age group 20-50 years. When Group A (cold saline) and Group B (normal saline) was evaluated.

Trismus (inter- incisal mouth opening) Group Comparison of mouth opening (in mm) between cold saline and normal saline group.

Table 2:

Interval	Cold saline		Normal saline		p-value
	Mean	SD	Mean	SD	
Pre-op	39.70	1.64	40.60	2.72	0.381
Day 3	33.00	5.25	31.60	3.89	0.507
Day 7	36.90	2.89	35.90	3.41	0.488

Independent t test; * indicates a significant difference at $p \leq 0.05$

There was a non-significant difference in the pre-operative mouth-opening between the two groups.

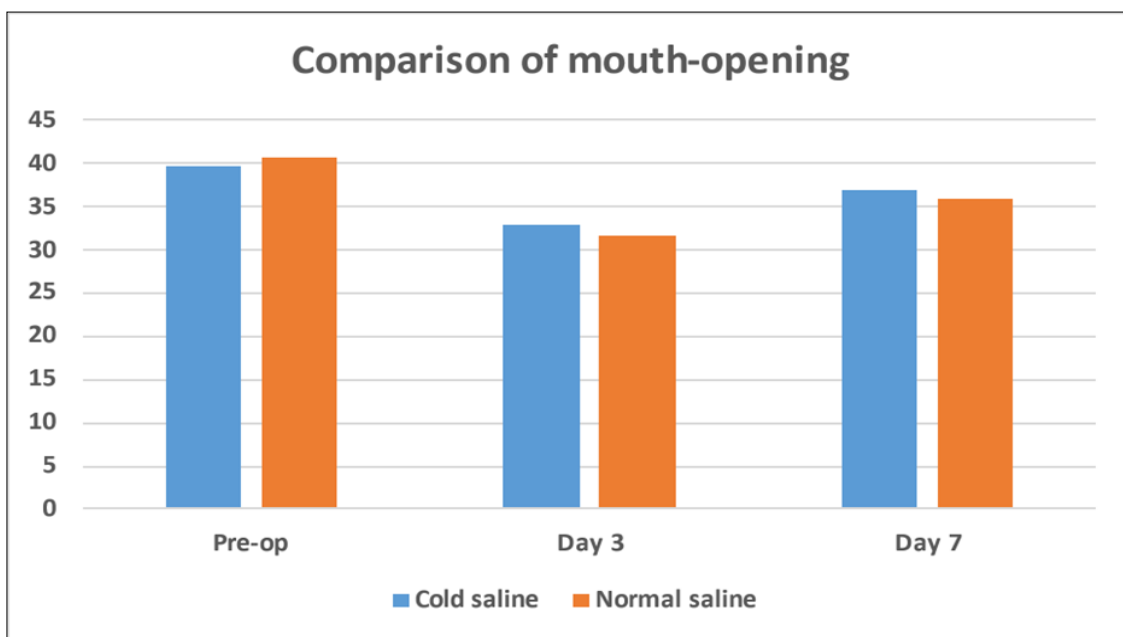


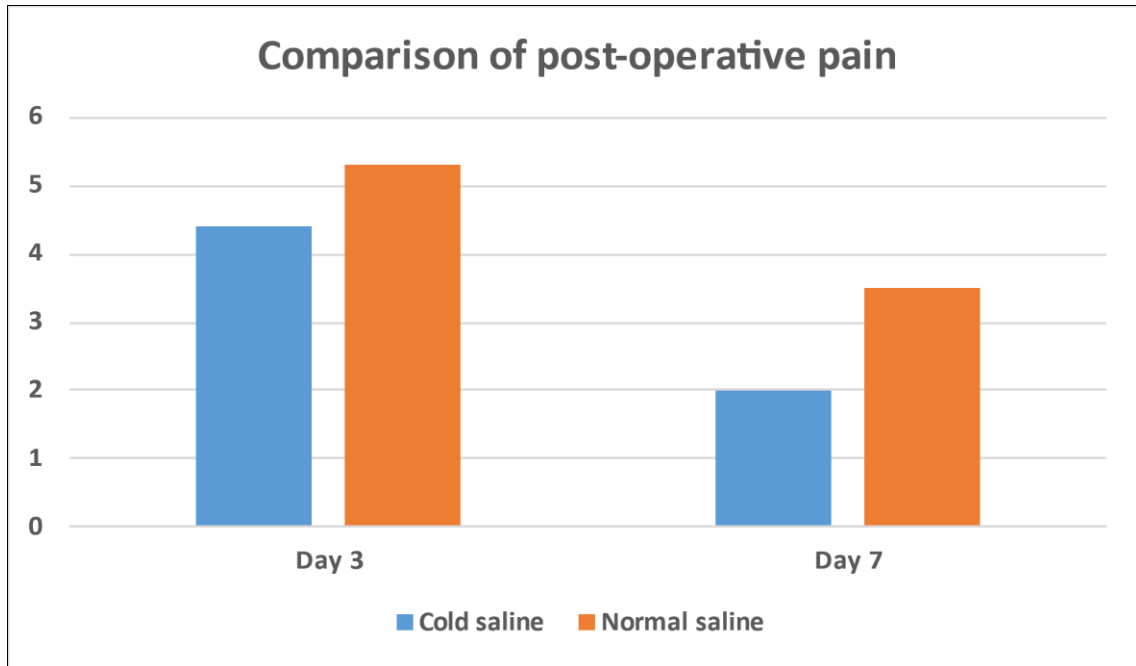
Table 3: Pain

Interval	Cold saline		Normal saline		p-value
	Mean	SD	Mean	SD	
Day 3	4.40	1.58	5.30	1.06	0.154
Day 7	2.00	1.25	3.50	1.58	0.030*

Independent t test; * indicates a significant difference at $p \leq 0.05$

On day 3, the mean post-operative pain in the cold saline group was (VAS)4.40 and that of the normal saline group was (VAS) 5.30. However, on day 7, the mean post-

operative pain in the cold saline group (VAS = 2.00) was significantly lower than in the normal saline group (VAS = 3.50).



Graph 3:

Swelling Comparison of swelling (s1) between cold saline and normal saline group

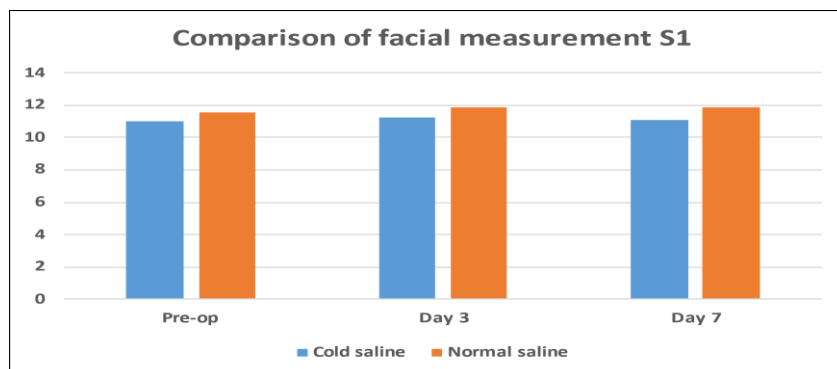
Table 4:

Interval	Cold saline		Normal saline		p-value
	Mean	SD	Mean	SD	
Pre-op	10.97	0.35	11.53	1.06	0.063
Day 3	11.25	0.39	11.88	1.04	0.023*
Day 7	11.07	0.42	11.83	1.10	0.029*

Mann Whitney test; * indicates a significant difference at $p \leq 0.05$

There was a non-significant difference in the pre-operative facial measurement S1 between the two groups. On day 3, the mean facial measurement S1 in the cold saline group (11.88) was significantly lower than in the normal saline

group (11.25). Similarly, on day 7, the mean facial measurement S1 in the cold saline group (11.07) was significantly lower than in the normal saline group (11.83).



Graph 4:

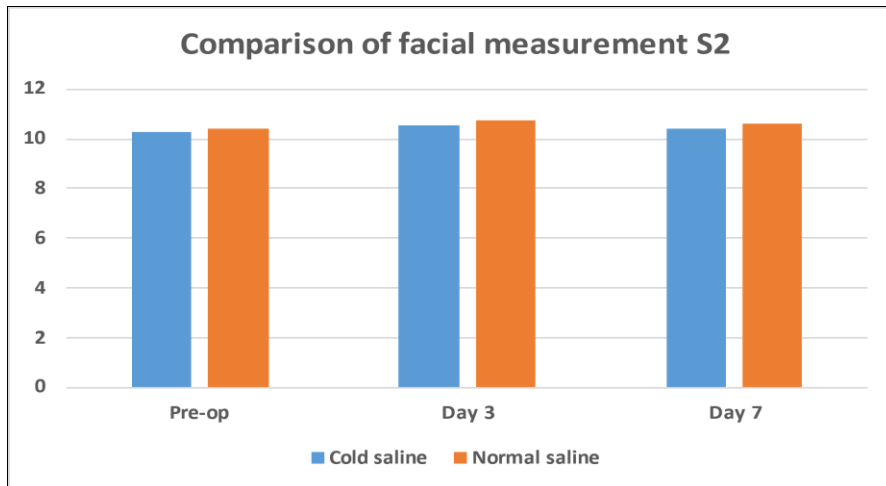
Comparison of swelling (s2) between cold saline and normal saline group

Table 5:

Interval	Cold saline		Normal saline		p-value
	Mean	SD	Mean	SD	
Pre-op	10.26	0.48	10.43	0.37	0.384
Day 3	10.56	0.42	10.75	0.27	0.243
Day 7	10.41	0.41	10.62	0.29	0.202

Mann Whitney test; * indicates a significant difference at p≤0.05

There was a non-significant difference in the pre-operative facial measurement S2 between the two groups. On day 3, the mean facial measurement S2 in the cold saline group (10.56) did not differ significantly from that of the normal saline group (10.75). On day 7, the mean facial measurement S2 in the cold saline group (10.41) did not differ significantly from that of the normal saline group (10.62).



Graph 5:

Comparison of swelling (s3) between cold saline and normal saline group

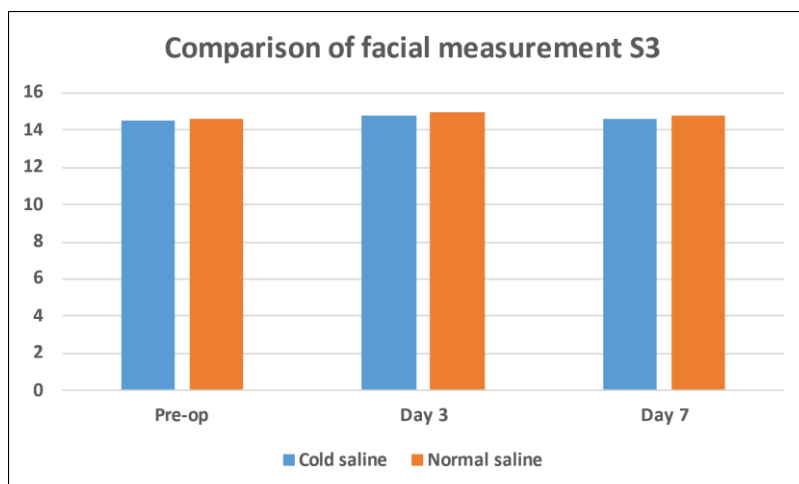
Table 6:

Interval	Cold saline		Normal saline		p-value
	Mean	SD	Mean	SD	
Pre-op	14.53	1.13	14.61	1.17	0.481
Day 3	14.75	1.13	15.01	1.26	0.218
Day 7	14.59	1.12	14.83	1.26	0.218

Mann Whitney test; * indicates a significant difference at p≤0.05

There was a non-significant difference in the pre-operative facial measurement S3 between the two groups. On day 7, the mean facial measurement S3 in the cold saline group

(14.59) did not differ significantly from that of the normal saline group (14.83).



Graph 6:

Discussion

Surgical extraction of third molars is one of the most common procedures in oral and maxillofacial surgery, often accompanied by postoperative complications such as pain, swelling, and alveolar osteitis. These issues can delay healing and significantly affect patients' quality of life. Effective wound irrigation is a critical step in managing these outcomes, as it removes debris, cools the surgical site, and supports tissue healing by preventing thermal injury and reducing bacterial load.

Irrigation also promotes proper wound hydration and enhances the transition from the inflammatory to proliferative phases of healing. The choice of irrigant is therefore crucial. Ideal irrigation solutions should be isotonic, non-toxic, non-hemolytic, easy to sterilize, and cost-effective. Hypotonic solutions can cause cell lysis and tissue edema, while hypertonic solutions may lead to dehydration and delayed healing.

Thermal injury to bone is a key concern during osteotomy. Rotary burs operating at 20,000–40,000 rpm generate significant heat, which may denature proteins, damage the organic matrix, and cause thermal necrosis. Studies by Koerner (1994) and Baker *et al.* (2013) emphasized the importance of cooling, recommending the use of saline or ice-cooled water to reduce thermal injury during drilling.

This study compared normal saline and cold saline (4°C) as irrigants in third molar surgery. Both solutions are isotonic and compatible with body tissues. While normal saline is widely used, cold saline demonstrated added benefits. Though no statistically significant differences in mouth opening (trismus) were observed between groups, swelling and pain outcomes favored the cold saline group.

Pain scores assessed by VAS showed no significant differences on day 3. However, by day 7, the cold saline group reported significantly lower pain (mean VAS 2.00 vs. 3.50; $p = 0.030$), indicating better late-stage recovery. Swelling measurements at S1 showed significant reductions in the cold saline group on both day 3 ($p = 0.023$) and day 7 ($p = 0.029$). While S2 and S3 showed no significant differences, there was a consistent trend toward reduced swelling in the cold saline group.

Conclusion

These findings support the use of cold saline during third molar surgery to reduce postoperative pain and swelling, potentially improving patient comfort and recovery without added cost or risk.

"Cold saline irrigation after mandibular third molar surgery shows benefits in reducing postoperative pain and swelling by day 7, though it does not significantly affect trismus. However, the small sample size limits the findings, and larger studies are needed for confirmation."

References

- Pillai AK, Thomas S, Paul G, Singh SK, Moghe S. Incidence of impacted third molars. A radiographic study in People's Hospital, Bhopal, India. *Journal of oral biology and craniofacial research*,2014;1:4(2):76-81.
- Agarwal S, Bargoti G, Dheer A, Garg BG, Roy B. Comparison of Normal Saline Irrigation with Cold Normal Saline in Surgical Removal of Lower Wisdom Tooth. A Pilot Study. *University Journal of Dental Sciences*,2022;6:8(3).
- Kalai Selvan S, Ganesh SK, Natesh P, Moorthy MS, Niazi TM, Babu SS, *et al.* Prevalence and pattern of impacted mandibular third molar. An institution based retrospective study. *Journal of Pharmacy and Bioallied Sciences*,2020;1:12(S1): S462-7.
- Lee CT, Zhang S, Leung YY, Li SK, Tsang CC, Chu CH, *et al.* Patients' satisfaction and prevalence of complications on surgical extraction of third molar. Patient preference and adherence,2015;10:257-63.
- Kim SJ, Yoo J, Kim YS, Shin SW. Temperature change in pig rib bone during implant site preparation by low-speed drilling. *Journal of Applied Oral Science*,2010;18:522-7.
- Ghosh D, Bhardwaj S, Koyalada S, Mahajan B, Verma S, Nayak B, *et al.* Comparison of efficacy of ozonated water, normal saline, and povidone-iodine after surgical removal of impacted mandibular third molars. A cross-sectional study. *Journal of Family Medicine and Primary Care*,2020;1:9(8):4139-44.
- Chong JK, Samsudin AD, Ma MS. The efficacy of 3 irrigating solution in surgical removal of lower wisdom tooth: a pilot study. *Arch Orofac Sci*,2016;1:11(1):1-6.
- Sruthy TV, Roshni A, Aslam S, Cherian MP, Soman S, Akhila K. Low concentration Povidone-iodine and Normal Saline as Irrigant on Reducing Postoperative Complications after the Third-molar Surgery: A Comparative Study. *The Journal of Contemporary Dental Practice*,2022;1:23(7):733-8.
- Urvi s, haren p, hiren p, bijal b, hitesh d. Efficacy of chlorhexidine versus betadine as an irrigating agent during removal of bilateral impacted lower third molars. *Pakistan oral & dental journal*,2014;1:34(2).
- Isler SC, Cansiz E, Tanyel C, Soluk M, Selvi F, Cebi Z, *et al.* The effect of irrigation temperature on bone healing. *International journal of medical sciences*,2011;8(8):704.
- Sener BC, Dergin G, Gursoy B, Kelesoglu E, Slih I. Effects of irrigation temperature on heat control *in vitro* at different drilling depths. *Clinical oral implants research*,2009;20(3):294-8.
- Kondo S, Okada Y, Iseki H, Hori T, Takakura K, Kobayashi A, *et al.* Thermological study of drilling bone tissue with a high-speed drill. *Neurosurgery*,2000;1:46(5):1162-8.
- Eriksson AR, Albrektsson T. Temperature threshold levels for heat-induced bone tissue injury: a vitalmicroscopic study in the rabbit. *The Journal of prosthetic dentistry*,1983;50(1):101-7.
- Yaghmaei M, Heidari S, Shahoun H, Yavari AS. comparison of betadine and normal saline in the irrigation of tooth socket on the complications after surgical removal of impacted wisdom teeth. *journal of dental school shahid beheshti university of medical scienc*,2006;23(4-66):683-688.
- Eriksson RA, Albrektsson T, Magnusson BJ. Assessment of bone viability after heat trauma: a histological, histochemical and vital microscopic study in the rabbit. *Scandinavian journal of plastic and reconstructive surgery*,1984;1:18(3):261-8.
- Hillery MT, Shuaib I. Temperature effects in the drilling of human and bovine bone. *Journal of Materials Processing Technology*,1999;30:92:302-8.
- Vijayakumar G, Sundaram GA, Kumar SP, Krishna VK, Krishnan M. Comparison of the Effectiveness of

- Four Different Irrigation Solutions on Postoperative Sequelae in Patients Undergoing Lower Third Molar Surgery: A Prospective Study. *Cureus*,2023:15(12).
18. Reddy PA, Wahab PU, Jagadish V, Murugan PS. Comparison of two irrigation solutions in the surgical removal of the mandibular third molars-A randomized trial. *Journal of Pharmaceutical Research International*,2020:9:32(28):28-35.
 19. Scott J, Huskisson EC. Graphic representation of pain. *Pain*,1976:1:2(2):175-84.
 20. Mc Grath C, Comfort MB, Lo EC, Luo Y. Changes in life quality following third molar surgery—the immediate postoperative period. *British dental journal*,2003:194(5):265-8.
 21. Freudlsperger C, Deiss T, Bodem J, Engel M, Hoffmann J. Influence of lower third molar anatomic position on postoperative inflammatory complications. *Journal of oral and maxillofacial surgery*,2012:1:70(6):1280-5.