



Comprehensive smile designing for correction of severely proclined maxillary anterior Teeth: A clinical case report

Dr. Anshadha Yede, Dr. Manish Chadha, Dr. Shyamolima Hazarika

Pacific dental college Udaipur, Rajasthan, India

Abstract

Severe proclination of maxillary anterior teeth can adversely affect facial aesthetics, lip competence, and smile harmony. This case report describes the esthetic rehabilitation of a 46-year-old female patient presenting with maxillary diastema and mobile mandibular anterior teeth. Orthodontic correction was declined by the patient, and a prosthetic approach was planned using Digital Smile Designing (DSD) with Exocad software. The digital workflow allowed precise treatment planning, improved communication with the patient, and ensured predictable esthetic and functional outcomes, resulting in satisfactory smile enhancement and patient satisfaction. Diagnostic mock-ups, provisional restorations, and crown lengthening were employed to optimize tooth proportions and inclination. Definitive rehabilitation was completed with multilayered zirconia crowns from canine to canine in the maxillary arch and from first premolar to first premolar in the mandibular arch.

Keywords: Smile designing, digital smile design, proclined anterior teeth, esthetic dentistry, zirconia crowns, prosthodontic rehabilitation

Introduction

Facial appearance plays an important role in interpersonal communication and psychological well-being, and the smile is considered one of the most important determinants of facial attractiveness. Contemporary dentistry has therefore evolved from a treatment philosophy primarily focused on restoring function to one that also emphasizes esthetics and patient expectations. Within this framework, smile designing has become an essential component of modern esthetic dentistry, allowing clinicians to evaluate and enhance the relationship between teeth, gingiva, lips, and facial structures [1].

Smile designing involves a detailed assessment of several parameters, including tooth shape and size, alignment, gingival contour, lip dynamics, and overall facial proportions. Careful evaluation of these factors helps clinicians develop treatment plans that produce a balanced and harmonious smile. Because dental esthetics is influenced by multiple anatomical and functional components, successful rehabilitation often requires a multidisciplinary approach involving prosthodontics, periodontics, orthodontics, and restorative dentistry [2, 3].

Recent advances in digital technology have significantly improved the accuracy and predictability of esthetic dental treatment. Digital Smile Design (DSD) allows clinicians to analyze facial and dental parameters using digital photographs, intraoral scans, and specialized software. This approach enables simulation of the expected treatment outcome before initiating definitive procedures, thereby improving communication among the dentist, laboratory technician, and patient [3, 4, 5].

Proclination of anterior teeth is a frequently encountered esthetic concern in dental practice. Excessive labial inclination of maxillary anterior teeth may adversely affect

facial profile, increase overjet, and result in lip incompetence, thereby compromising smile harmony. In addition to esthetic issues, such conditions may also contribute to occlusal disturbances and phonetic difficulties [6, 7]. Therefore, careful diagnosis and comprehensive treatment planning are essential to restore both functional balance and esthetic appearance.

Various treatment options have been proposed for correcting proclined anterior teeth. Orthodontic therapy is generally considered the most conservative approach; however, patient preferences, treatment duration, and other clinical factors often influence the final treatment decision. In certain cases, prosthodontic rehabilitation using crowns or veneers may provide an effective alternative for achieving satisfactory esthetic results within a shorter treatment period [8].

The present case report describes the prosthodontic rehabilitation of a patient with severely proclined anterior teeth using a comprehensive smile designing protocol. Through digital planning, provisional evaluation, and definitive prosthetic treatment, the aim was to enhance smile esthetics while maintaining functional stability and patient satisfaction.

Case Presentation

A 46-year-old female patient reported to the Department of Prosthodontics, Crown and Bridge with complaints of spacing in the upper anterior region and mobility of the lower anterior teeth. Clinical examination revealed Grade II mobility in teeth 32, 31, 41, and 42. Generalized spacing was observed in the maxillary anterior region along with increased overjet and overbite. Extraoral assessment revealed a bilaterally symmetrical facial profile with evidence of lip incompetence (fig 1)

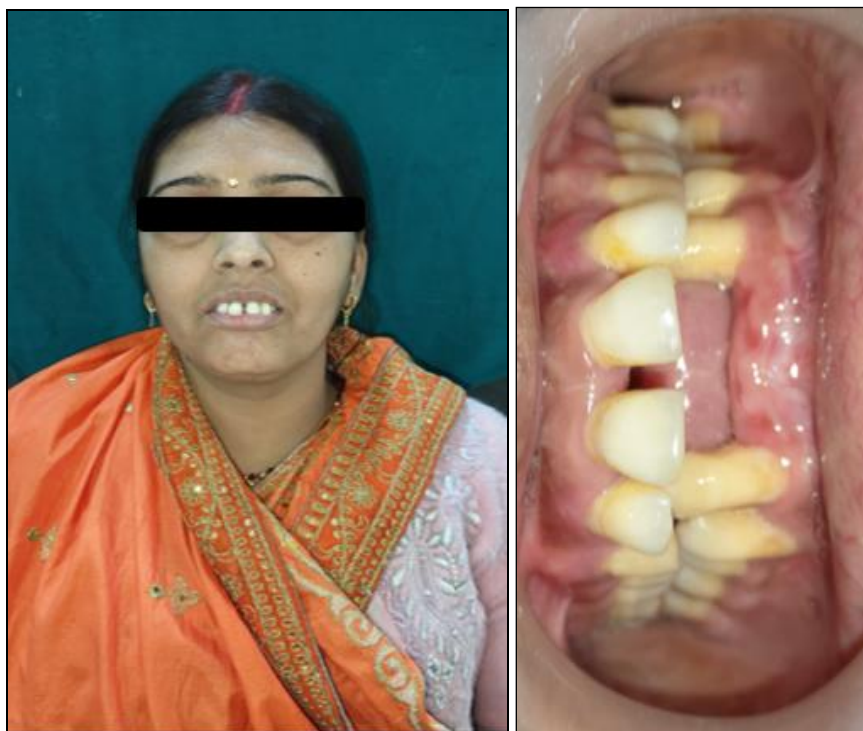

Fig 1: pre operative photograph

Based on the clinical findings, orthodontic therapy was initially recommended to correct the spacing and proclination of the anterior teeth. However, the patient declined orthodontic treatment because of the anticipated treatment duration and expressed a preference for a faster esthetic solution. Therefore, a prosthetic treatment strategy was formulated to address both the spacing in the maxillary anterior region and the mobility of the mandibular anterior teeth.

Diagnostic impressions were obtained as part of the preliminary evaluation. A digital workflow was then incorporated into the treatment plan, and Digital Smile Designing (DSD) using Exocad software was selected for smile analysis and planning. The procedure and proposed treatment plan were thoroughly explained to the patient, and informed consent was obtained. A diagnostic mock-up was prepared on the cast to demonstrate the expected esthetic outcome and to facilitate patient understanding and approval.

Following clinical evaluation and patient consent, it was decided to restore the dentition with intentional root canal treatment followed by placement of multilayered zirconia crowns. The prosthetic rehabilitation was planned from canine to canine in the maxillary arch and from first premolar to first premolar in the mandibular arch.

The patient was initially referred to the Department of Oral and Maxillofacial Surgery for extraction of teeth 42, 21, 31, and 32. After an adequate healing period, the patient was recalled for prosthodontic procedures. Tooth preparation was carried out using a straight fissure diamond bur, and a shoulder finish line was established with respect to teeth 13, 12, 11, 21, 22, 23, 44, 43, 33, and 34 (fig 2). Due to the severe proclination of the maxillary anterior teeth, the apparent clinical crown height was reduced following tooth preparation. To improve esthetic proportions and provide adequate tooth structure for restoration, a crown lengthening procedure was performed in relation to teeth 12, 11, 21, and 22.

After completion of tooth preparation, an impression was made using irreversible hydrocolloid for fabrication of provisional restorations, and an intraoral scan (fig 3) was also recorded. A provisional prosthesis fabricated from PMMA was delivered on the same day and temporarily cemented. However, the patient expressed dissatisfaction with the provisional restoration, particularly with respect to crown height and the inclination of the anterior teeth.

To improve the esthetic outcome, the intraoral scan data were sent to the dental laboratory for fabrication of a 3D-printed provisional restoration. During the second appointment, the 3D-printed provisional prosthesis was tried intraorally. Adjustments in crown height and tooth inclination were carried out according to the patient's esthetic expectations (fig 4). Once the patient approved the modified provisional restoration, a new intraoral scan was obtained with the provisional prosthesis in position (fig 5).

The scan obtained after tooth preparation and the scan of the approved provisional restoration were subsequently superimposed using Exocad software and CAD file was generated for final prosthesis (fig 6). This digital reference served as a guide for designing and fabricating the definitive prosthesis.

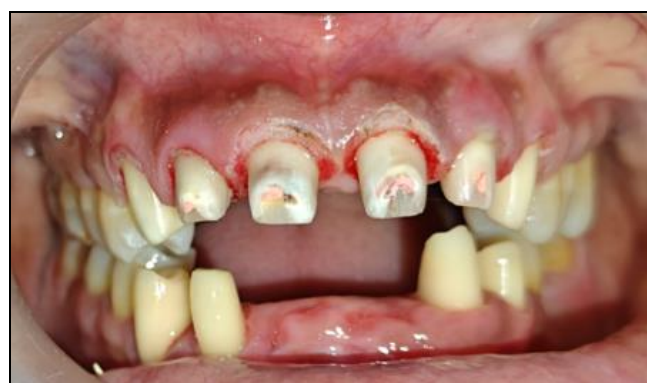

Fig 2: tooth preparation and gingivectomy

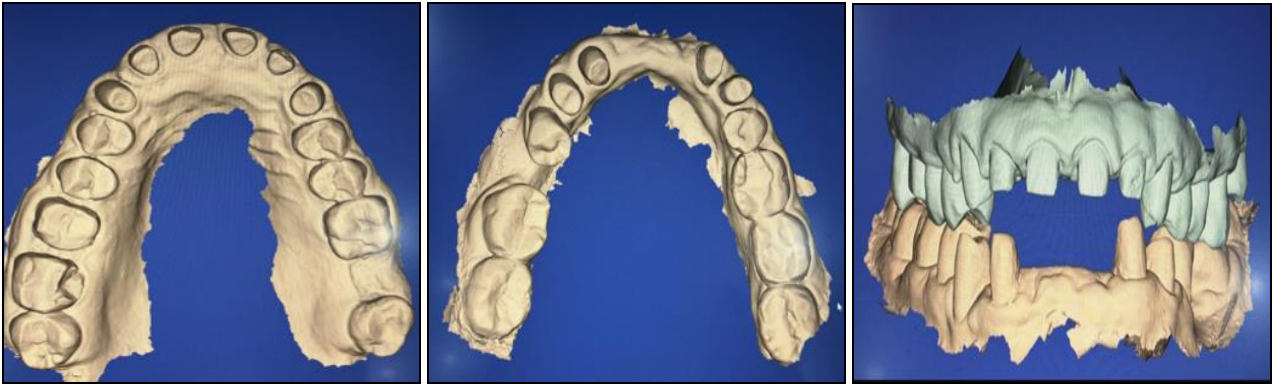

Fig 3: intra oral scan of the tooth preparation (scan1)

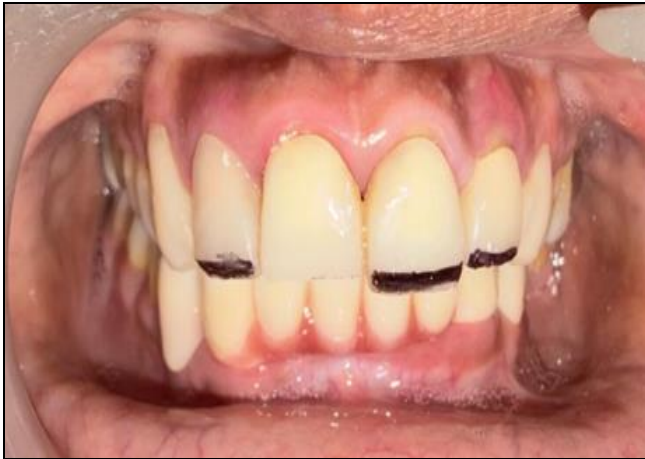

Fig 4: adjustment of temporary

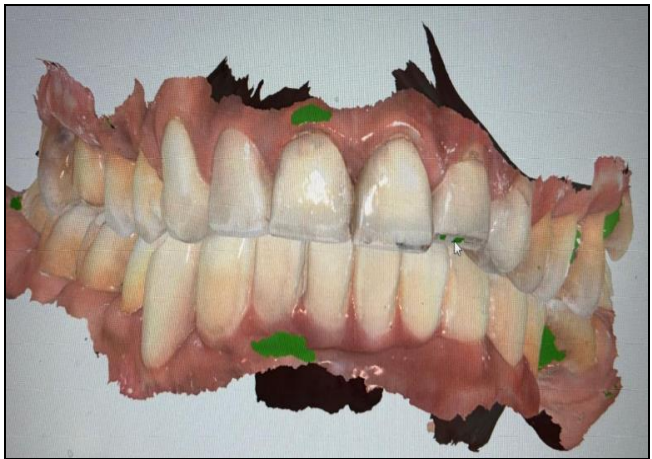

Fig 5: Intra oral scan of temporary (scan 2)

At the third appointment, the patient was scheduled for cementation of the definitive restorations. The internal surfaces of the all-ceramic crowns were etched using 8% hydrofluoric acid, rinsed thoroughly, and dried. A silane coupling agent was then applied to the internal surfaces and allowed to air dry. The prepared tooth surfaces were etched with 37% orthophosphoric acid for 30 seconds, rinsed thoroughly, and dried. A bonding agent was applied and

light cured. The crowns were subsequently cemented using resin cement, and excess cement was carefully removed. Post-operative instructions were provided, and the patient was recalled after one week. At the follow-up visit, no signs of inflammation or complications were observed, and the patient reported satisfaction with the esthetic outcome of the treatment.

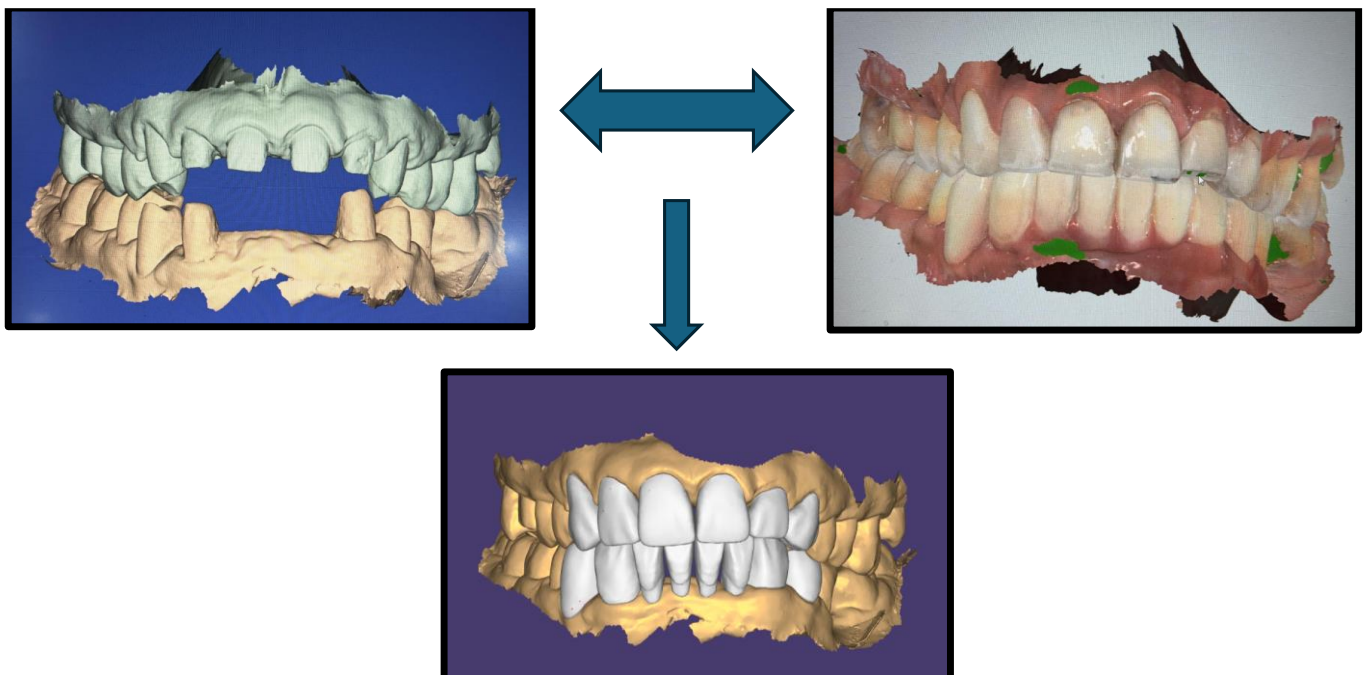


Fig 6: superimposition of scan 1 and scan 2

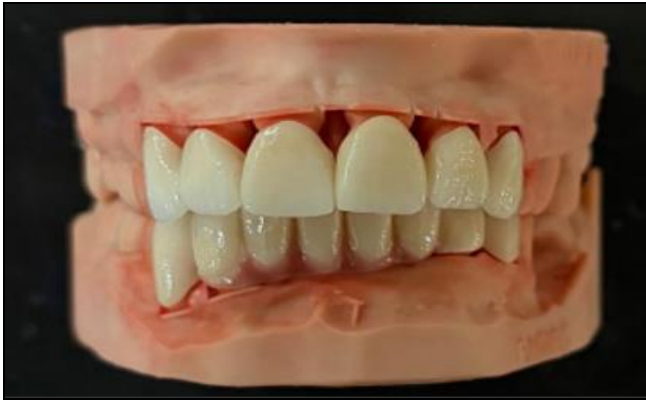

Fig 8: definitive prosthesis 3 layered zirconia crowns

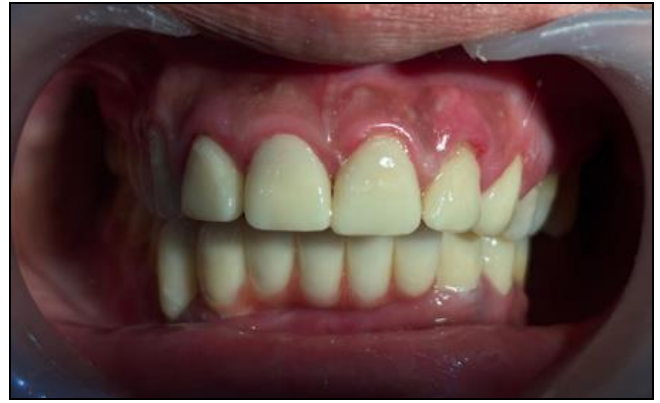

Fig 9: Final cementation of final prosthesis

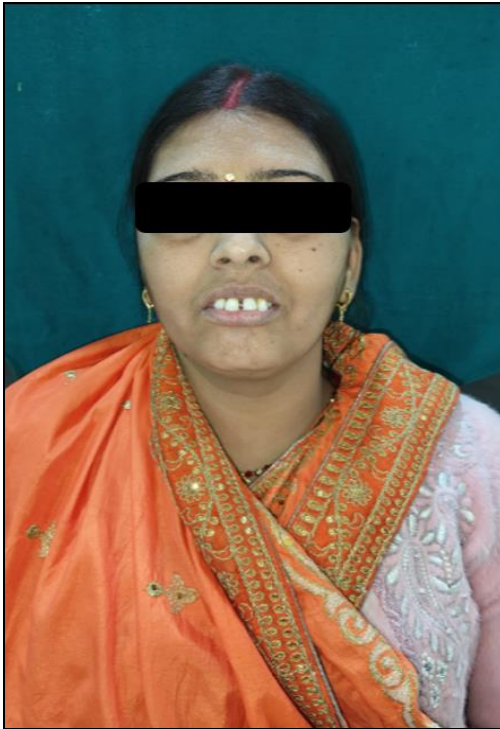

Fig 10: (a) pre operative photograph (b) post operative photograph

Discussion

In recent years, patient expectations regarding dental treatment have increasingly focused on achieving improved facial esthetics in addition to restoring oral function. Smile designing plays a key role in fulfilling these expectations by enabling clinicians to evaluate the interaction between dental structures and facial features. A systematic assessment of tooth proportions, gingival contours, and lip dynamics allows development of individualized treatment plans that enhance both esthetic appearance and functional performance.

In the present case, the patient presented with generalized spacing in the maxillary anterior region together with severe proclination and mobility of the mandibular anterior teeth. Such conditions can negatively influence smile harmony, facial profile, and lip competence. Although orthodontic treatment is widely regarded as the most conservative approach for correcting tooth proclination and diastema, patient preference and treatment duration often influence the choice of therapy. In this case, the patient declined orthodontic intervention and requested a faster esthetic solution, leading to the selection of a prosthetic rehabilitation approach.

Digital Smile Designing (DSD) played an important role in treatment planning and execution. Digital analysis enabled accurate evaluation of tooth proportions, inclination, and overall smile characteristics. The digital workflow also facilitated effective communication between the clinician and the dental laboratory, thereby improving the precision of the definitive prosthetic restorations. Additionally, superimposition of the preparation scan and the provisional restoration scan provided a reliable digital reference for fabrication of the final prosthesis.

Provisional restorations served as an important diagnostic step in evaluating esthetics and function prior to definitive treatment. Although the initial PMMA provisional restoration allowed preliminary assessment, patient dissatisfaction regarding crown height and tooth inclination necessitated fabrication of a modified 3D-printed provisional restoration. This allowed more precise adjustments and enabled the patient to visualize and approve the proposed esthetic outcome before fabrication of the final prosthesis. Crown lengthening was also performed to improve clinical crown height and establish appropriate tooth proportions in the maxillary anterior region.

The final prosthetic rehabilitation using multilayered zirconia crowns resulted in significant improvement in both esthetics and function. Zirconia restorations are widely recognized for their excellent mechanical strength, biocompatibility, and favorable esthetic properties, making them suitable for anterior restorative procedures. The combination of digital treatment planning, provisional evaluation, and appropriate restorative materials contributed to predictable treatment outcomes and improved patient satisfaction.

Conclusion

Smile designing provides a systematic approach for managing complex esthetic concerns in dental practice. In the present case, the use of digital smile planning, provisional restorations, and prosthodontic rehabilitation allowed successful correction of severely proclined anterior teeth and associated spacing. The digital workflow facilitated accurate treatment planning and improved communication with the patient by allowing visualization of the anticipated result prior to definitive therapy. Restoration with multilayered zirconia crowns contributed to both functional stability and an improved esthetic appearance. This case highlights how the integration of digital technology with careful clinical planning can lead to predictable and patient-centered esthetic rehabilitation.

References

1. Yue Z, Luo Z, Hou J, Zhang H. Application of 3D digital smile design based on virtual articulation analysis in esthetic dentistry: A technique. *J Prosthet Dent*,2025;133(1):24-30. doi:10.1016/j.prosdent.2023.11.014.
2. Haberal M, Bayraktar Y. Smile design with periodontal-restorative treatment: A case report. *Int Dent J*,2024;74(Suppl):S336. doi:10.1016/j.identj.2024.07.397.
3. Kumar T. Smile designing: A multidisciplinary approach for dental aesthetics. *Int J Med Res Health Sci*,2023;12(3):1-5
4. Lambodaran G, Jaisudhaa M, Shankar MS, Vigneswaran S, Lakshmi S, Annapoorni H. Smile designing using DSD: A case report. *Med Leg Update*,2020;20(4):2222-2227.
5. Sanchez-Lara A, Chochlidakis KM, Lampraki E, Molinelli R, Molinelli F, Ercoli C. Comprehensive digital approach with the Digital Smile System: A clinical report. *J Prosthet Dent*,2019;121(6):871-875. doi:10.1016/j.prosdent.2018.10.012.
6. Madan N, Raisinghani D, Prasad A, Sarraf N, Gupta R. Designing a smile: A case report. *Int J Appl Dent Sci*,2017;3(2):Part A.
7. Ragul I, Aravind P, Joy J, Peter S, Shabana, Kanakamani. Prosthodontic management of severely proclined and mobile dentition with spacing using digital smile designing: A case report. *J Indian Prosthodont Soc*, 2024, 14(2).
8. Nipane R, Sundarkar P, Thombare B, Dammani B, Wankhade B, Shambharkar S, Ajmire S. *et al.* Smile designing using recurring esthetic dental proportion and aesthetic pre-evaluative temporary technique with porcelain laminate veneers: A case report. *Int J Res Med Sci*,2023;11(9):3456-3459. doi:10.18203/2320-6012.ijrms20232809
9. Lambodaran G, Jaisudhaa M, Shankar MS, Vigneswaran S, Lakshmi S, Annapoorni H. Smile designing using digital smile design: A case report. *Med Leg Update*, 2020, 20(4).
10. Singh S, Singh A, Biswas K, Chaturvedi A. Smile designing: A case report. *WARIPLEX Indian J Res*, 2018, 7(8).